



Cranio-maxillofacial

Implant Directions®

Vol.16 N° 1

January 2022

English Edition



GOODBYE „OSSEOINTEGRATION“

STATEMENT OF THE INTERNATIONAL IMPLANT FOUNDATION, MUNICH GERMANY

Abhishare Reddy N., Ahmed N., Ahteskam M., Alejnikov I., Antonov A., Anosh R., Asenjo M., Boborovskij S., Bakanova O., Balan R., Bhat A., Corcodel M., Cuervo A., Deikun D., Dhaval V., Diaz P., Diez Diez F., Fodor C., Fabritius T., Fazekas N., Fedoseev N., Fedoseev V., Fedotov A., Frankun Dr., Hoffer L., Garcia R., Mohamed G., Gaur V., Genchev G., Ghate M., Golisheva V., Gombkoto G., Gonzalez D., Gsadiyelli S., Gubaidulin N., Huber G., Ibrahimov I., Ihde S., Ihde A., Iovan C., Jovanovic T., Jung L., Kalinina O., Kasmal A., Karathelcers R., Kanatsdande J., Kelemen P., Kolentzova V., Kolhe R., Kotwal T., Kozakov B., Ksnisacor P., Kumal R S., Kumar M., Krasnova S., Krishna L., Lanesi P., Lell I., Magadov R., Malchev L., Mahajan M., Maisara I., Maheshwari N., Mahoorkar S., Makarchuk I., Maier A., Manjarrz LC., Martinez Silva J., Martinez Nieto I., Memon Z., Mhalte R., Milane A., Modi R., Mohd Fahim A., Namdakov N., Navreen G., Novikov S., Paibat A., Paneriya P., Pantelic M., Pascu C., Patil A., Patel H., Patel MA., Peñaranda S., Perumal M., Prasad SA., Rahmaan F., Rajan S., Rajendiran S., Ramazanov R., Ramazanov S., Ranjit Dr., Rathad R., Reddy N., Reddi L., Reddy S., Rivera Navarro A., Romero A., Rostov A., Rubiano O., Savchenko O., Sadigade A., Santiago Lopez R., Sayed S., Sergeev G., Serrano Gomez J., Sethuraman E., Sipic O., Sreenivas P., Schmojlov A., Solano A., Suboth C., Tanasa D., Todevski K., Torres D., Trofymchuk H., Tudose B., Umarji S., Vares Y., Vares J., Vargas M., Viveros P., Wage L., Yamshidar B., Varsada R., Zahariev N., Zacharov V., Zubaro F.

OFFPRINT



The Foundation of Knowledge

Editorial board

Managing editor

Dr. Łukas Pałka
regmed.klinika@gmail.com

Dr. Vivek Gaur
drvivekgaur@yahoo.co.in

Coordinating editor

Joanna Dołbaczuk
j.dolbaczuk@gmail.com

Editorial board (in alphabetic order)

Dr. Muhammad Alobayat, Palestine
Dr. Pablo Diaz, Ecuador
Dr. Anita Doshi, India
Dr. Marcos Daniel Gonzales, Colombia
Dr. Georg Huber, Germany
Prof. Dr. Vitomir S. Konstantinovic, Serbia
Dr. Alexander Lazarov, Bulgaria
Dr. Igor Lell, Germany
Dr. Valeri Lysenko, Ukraine
Dr. Werner Mander, Spain
Dr. Juri Mitrushenkov, Russia
Dr. Mahendra Perumal, India
Dr. Andrii Shmojlov, Russia
Prof. Dr. Jan Vares, Ukraine

Evidence reports and Critical Appraisals

IF Research & Evidence Dept.

Annual Subscription

Euro 2.800

Copyright

Copyright ©2006 - 2022 by
International Implant Foundation
DE- 80802 Munich / Germany
www.implantfoundation.org

Contact

publishing@implantfoundation.org

CMF.Impl.dir.

ISSN 1864-1199
e-ISSN 1864-1237

Disclaimer

Hazards

Great care has been taken to maintain the accuracy of the information contained in this publication. However, the publisher and/or the distributor and/or the editors and/or the authors cannot be held responsible for errors or any consequences arising from the use of the information contained in this publication. The statements or opinions contained in editorials and articles in this publication are solely those of the authors thereof and not of the publisher, and/or the distributor, and/or the IIF.

The products, procedures and therapies described in this work are hazardous and are therefore only to be applied by certified and trained medical professionals in environment specially designed for such procedures. No suggested test or procedure should be carried out unless, in the user's professional judgment, its risk is justified. Whoever applies products, procedures and therapies shown or described in this publication will do this at their own risk. Because of rapid advances in the medical science, IF recommends that independent verification of diagnosis, therapies, drugs, dosages and operation methods should be made before any action is taken.

Although all advertising material which may be inserted into the work is expected to conform to ethical (medical) standards, inclusion in this publication does not constitute a guarantee or endorsement by the publisher regarding quality or value of such product or of the claims made of it by its manufacturer.

Legal restrictions

This work was produced by IF Publishing, Munich, Germany. All rights reserved by IF Publishing. This publication including all parts thereof, is legally protected by copyright. Any use, exploitation or commercialization outside the narrow limits set forth by copyright legislation and the restrictions on use laid out below, without the publisher's consent, is illegal and liable to prosecution. This applies in particular to photostat reproduction, copying, scanning or duplication of any kind, translation, preparation of microfilms, electronic data processing, and storage such as making this publication available on Intranet or Internet.

Some of the products, names, instruments, treatments, logos, designs, etc. referred to in this publication are also protected by patents and trademarks or by other intellectual property protection laws (eg. «IF», «IIF» and the IF-Logo) are registered trademarks even though specific reference to this fact is not always made in the text.

Therefore, the appearance of a name, instrument, etc. without designation as proprietary is not to be construed as a representation by publisher that it is in the public domain.

Institutions' subscriptions allow to reproduce tables of content or prepare lists of Articles including abstracts for internal circulation within the institutions concerned. Permission of the publisher is required for all other derivative works, including compilations and translations. Permission of the publisher is required to store or use electronically any material contained in this journal, including any article or part of an article. For inquiries contact the publisher at the address indicated.



Goodby “Osseointegration”

Statement of the International Implant Foundation,
Munich Germany

Autoren

Abhishare Reddy N (IN), Ahmed N (IN), Ahteskam M (IN), Alejnikov I (RU), Antonov A (BG), Anosh R (IN), Asenjo M (Dom Rep), Boborovskij S (RU), Bakanova O (RU), Balan R (DE), Bhat A (IN), Corcodel M (RO), Cuervo A (COL), Deikun D (RU), Dhaval V (IN), Diaz P (GUA), Diez Diez F (ES), Fodor C (RO), Fabritius T (DE), Fazekas N (HU), Fedoseev N (RU), Fedoseev V (RU), Fedotov A (RU), Frankun Dr (IN), Hoffer L (HU), Garcia R (MEX), Mohamed G (BG), Gaur V (IN), Genchev G (BG), Ghate M (IN), Golisheva V (RU), Gombkoto G (HU), Gonzalez D (COL), Gsadiyelli S (IN), Gubaidulin N (RU), Huber G (DE), Ibrahimov I (RU), Ihde S (DE), Ihde A (BY), Iovan C (RO), Jovanovic T (SRB), Jung L (DE), Kalinina O (RU), Kasmal A (IN), Karathelcers

R (IN), Kanatsdande J (IN), Kelemen P (HU), Kolentzova V (BG), Kolhe R (IN), Kotwal T (IN), Kozakov B (RU), Ksnisacor P (IN), Kumal R S (IN), Kumar M (IN), Krasnova S (RU), Krishna L (IN), Lanesi P (IN), Lell I (DE), Magadov R (RU), Malchev L (BG), Mahajan M (IN), Maisara I (RU), Maheshwari N (IN), Mahoorkar S (IN), Makarchuk I (UA), Maier A (DE), Manjarrz LC (COL), Martinez Silva J (ED), Martinez Nieto I (ES), Memon Z (IN), Mhalte R (IN), Milane A (IN), Modi R (IN), Mohd Fahim A (IN), Namdakov N (RU), Navreen G (IN), Novikov S (RU), Paibat A (IN), Paneriya P (IN), Pantelic M (SRB), Pascu C (RO), Patil A (IN), Patel H (IN), Patel MA (IN), Peñaranda S (COL), Perumal M (IN), Prasad SA (IN), Rahmaan F (IN), Rajan S (IN), Rajendiran S (IN), Ramazanov R (UA), Ramazanov S (UA),

Ranjit Dr (IN), Rathad R (IN), Reddy N (IN), Reddi L (IN), Reddy S (IN), Rivera Navarro A (MEX), Romero A (COL), Rostov A (RU), Rubiano O (COL), Savchenko O (RU), Sadigade A (RU), Santiago Lopez R (MEX), Sayed S (IN), Sergeev G (RU), Serrano Gomez J (MEX), Sethuraman E (IN), Sipic O (SRB), Sreenivas P (IN), Schmojlov A (RU), Solano A (COL), Suboth C (IN), Tanasa D (RO), Todevski K (MK), Torres D (Col), Trofymchuk H (UA), Tudose B (RO), Umarji S (IN), Vares Y (UA), Vares J (UA), Vargas M (COL), Viveros P (COL), Wage L (IN), Vamshidar B (IN), Varsada R (UA), Zahariev N (BG), Zacharov V (RU), Zubaro F (IN)

Correspondence address:

International Implant Foundation
Leopoldstr. 116
DE-80802 Munich/Germany
contact@implantfoundation.org

Published in cooperation with:

Jaipur Dental College, Department for
Prosthetics, Maharaj Vinayak Global Uni-
versity, 302021 Jaipur, Rajasthan, India

How to cite this article

Abhishare Reddy N., et al
Statement of the International Implants
Foundation, Munich
CMF Impl Dir 2022, 16: 3 - 11

Abstract

The authors (from their own experience and based on scientific literature) state that the old method of osseointegration, which had served the profession of dental implantology is outdated and full of flaws. It does not meet the expectations of the patients and causes severe problems the longer dental implant stay in the oral cavity.

The Technology of the Strategic Implant® has overcome the major problems which are associated to conventional oral implantology and of the method of "osseointegration".

Conventional oral implantology and the method of osseointegration is not the specialist standard any more today.

Keywords

Osseointegration, osseofixation, periimplantitis, specialist standard, oral implantology

For decades oral implantology was guided by the term “osseointegration”. We are told that this term stemmed from the “Osseointegration team” around P.I. Branemark and Prof. T. Albrektsson, and it describes the peaceful co-existence between living bone if in contact or near titanium. Following this, industry took over this observation and a new oral implantology resulted. The industries activities for marketing the term “osseointegration” and most of what was done then actually never was scientifically connected to the work of the “osseointegration team”.

It has to be mentioned here that from approximately 1956 onwards (i.e. decades before Mr. Branemark discovered the unique properties of bone near titanium bodies) oral implantology already had existed on a considerable scale and that since this time until the beginning of the medial propaganda for “osseointegration” implantologists worldwide had worked very successfully and even in immediate loading protocols.

After the implant industry entered the arena, each company tried to “make a difference” through *their* miracle-like implant surfaces. Surface enlarging through sand blasting and later done in combination with etching or anodization technologies became the Holy

Grail (and actually later the grave) of conventional oral implantology. Healing times were made popular, and the marketing focused on “the multi-piece screw implant”. Implants became expensive, healing times became necessary, and soon the term “Periimplantitis” was spreading through the population. Periimplantitis was not known as long as only polished implants had been used.

Since the middle of the 1990s dental implants were predominantly multi-piece designs, they automatically provided a large implant diameter, and their endosseous surfaces were rough. That is it, end of the line.

It remained unnoticed in the field of oral implantology, that in traumatology and orthopedic surgery rough implant surfaces were never used nor deemed an advantage, although they could be in use there with much less risk, due to the fact that these implants are installed in sterile body compartments. The advantages which “rough-implant-surface-manufacturers” claimed were never recognized in the field of traumatology. This should make us think.

For those rough oral implant surfaces a high price had to be payed by the patients: not only became the devices more

expensive due to the connected marketing, also bad long-term results were seen: since the beginning of the century large congresses around the world deal with the topic named "Periimplantitis". They actually deal with the question how a completely superfluous problem can be made the "state of the art", and how patients can be convinced to accept it and pay tribute with a lot of money and with their oral health to that Holy Grail. Albrektsson & team had revoked already in 2020 their theory of why and how osseointegration happened, but this remained widely unnoticed.

Large manufacturers (just as actually too many oral implant practitioners) refused to draw consequences out of the logical fact (a self-evident knowledge) that the **big implant diameters in combination with the rough surfaces are the cause of the problem**. Scientific results which proved exactly this were neglected and overseen in the vast body of useless and redundant (to a large extend falsified) scientific literature in our field.

Nowhere in other fields of medicine, the human body is operated towards the desired medical device. Always the device is chosen which fits the individual patient, - nowhere, except in conventional oral implantology as we will show:

A human heart is never first increased in size to fit to an initially too large artificial heart-flap, just to mention an example. Heart flaps are chosen to fit the anatomy which had to be dealt with.

In oral implantology such cinderella-procedures were made fashionable: instead of applying oral implants which fit the jaw bone right away, "bone augmentation procedures" were invented and became "state of the art". And: instead of using right away well-suited bone areas with high mineralization for implant anchorage, areas which are known to be prone to resorption were augmented, - e.g. the maxillary sinus. Bonefit® implants (a brand sold in the 1990s), did not fit the bone in most cases, but nobody was supposed to notice that. Unbelievable. Patients suffered, but they had no say in this game.

Bone augmentations can **never be part of immediate loading protocols**, because the augmented area cannot be put into function right away and because the augmentation site is to be infected through the inevitable opening between the implant and the mucosa. In immediate loading implantology bone is **rather removed than augmented** to create aesthetics, bone is never augmented in this technology. There is no need for

this. The border between oral implantology and cranio-facial rehabilitation has been blurred. All the forementioned publications reveal without mercy how useless and wrong many of the rules, assumptions and fears of conventional implantology are and that bone augmentations solely done for the installation of a 2-stage implant is a mistaken concept. The idea that (only) intricate implant surfaces (as advertised by the big implant manufacturers) allow early or immediate loading is a superstition, but it is not easy to erase this thinking from the brains of the “conventionals”.

The situation was not the same in all parts of the world: in remote corners of West-Germany and in France a fearless fraction of clear thinkers among implant practitioners refused already more than 20 years ago to follow the mainstream and they invented first the technology of lateral basal implants (e.g. Diskimplant® and BOI®) and later the Technology of the Strategic Implant®. The two types of devices do not look alike, but they have everything in common: basal implantology uses solely polished implant bodies, thin and polished mucosal penetration diameters, exclusively cortical anchorage (osseofixation) and immediate loading protocols. There is no need for “osseointegration” and healing times any more

if highly mineralized bone areas are utilized for anchorage. The concept of the emerging profile and performing bone augmentations is definitely “out”. And all this provided for all of our cases the possibility of immediate functional loading.

Over the years the fearless thinkers from central Europe made friends will think-alike implant practitioners around the world and since then this group has then come up with more than 380 international publications.

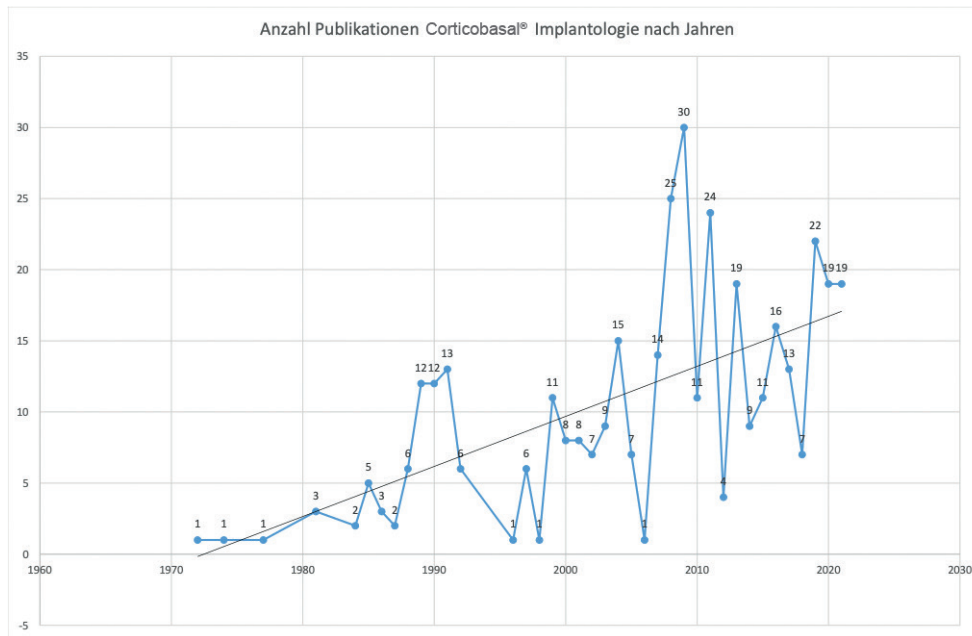


Fig.1: Overview on available publications in the field of Corticobasal® implants since 1970. The vast majority of these publications has been written by private practitioners, outside of universities.

They have proven with undisputable statistics that their concept works. Better than the mainstream concept, without the flaws which “osseointegrated” contains. While the “conventional implantologists” still perform bone augmentations and impose “healing times” to their customers, **the Thinkers** have started to catch the market. And neither this market nor the patients will ever run back to the old technology.

While the thinkers start their implant cases on Monday and finishing it on Wednes-

days, the “conventionals” finish after 18 months.

The thinkers never do bone augmentations, the “conventionals” do it in the majority of the cases.

The Thinkers show proven success rates of well over 95% on long term, the “conventionals” can't show anything better. Rather the opposite: if one would count those cases/implants where the treatment of the patient did not come to success *because it started with a non-successful*

bone augmentation, and if we would also count those implants which were never placed because the patient was sent away untreated because there was “not enough bone”, we would see the openly dramatic disaster which the “osseointegrators” cause. If we would apply the “Intent to Treat”-principle properly, then we would also count those cases and implants as a failure, which had not been placed because the bone augmentation was refused by the patient (for whatever reasons).

Plus: The Thinkers with their polished surfaces never create “Periimplantitis”. That’s a proven fact today.

And: If a conventional fails due to periimplantitis it creates a much worse condition than if it had failed before osseointegration. This way uncountable patients have been seriously damaged regarding their oral health by the “osseointegrators” all around the world.

And: The Thinkers can show that they improve the quality of life with their therapy. This was new in oral implantology, - so far patients mainly suffered.

Looking at today’s clinical reality, we have to accept that the concept of the Strategic Implant®, the Corticobasal® im-

plants and alike have overcome all the shortcomings and problems of traditional implantology and of the concept of “osseointegration”. Bone augmentations and “healing times” are today not state of the art any more for standard cases in oral implantology, they are not the “specialist standard”.

This raises the question for how long the “conventionals” may continue to ignore the other treatment possibilities and fight against the winds of change instead of setting the sails to use them? For how long will the old method be **ethically** accepted? How can they justify “bone augmentation”? How to justify (the unnecessary) “healing times”?

Soon the cumulative knowledge in the tribe of our patients will understand that **“Periimplantitis” happens only because the wrong implants were chosen.** What will the “conventionals” tell them then?

The method of **“osseofixation”**, as it has been used in the field of traumatology and (general) orthopedic surgery since the 1970s, has been successfully transferred into the field of oral and craniofacial implantology. The Technology of the Strategic Implant® is ready for use for every single treatment provider. It is not only an alternative to the 2-stage implants, it

is even a perfect alternative to repairing an aging dentition of our patients again and again. This technology frees the patients from the burdens of their own teeth.

Neither the methods “**osseointegration**” nor “**bone augmentations**” are known in the field of traumatology. Today they lose very fast their field of application in oral implantology.

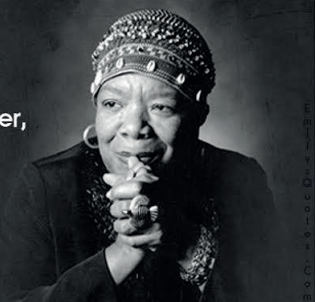Good old “osseointegration” steps off the stage of oral implantology, its clinical indications are today only very limited.

The “Specialist Standard” in oral implantology has changed.

Goodbye Osseointegration!

Do the best you can until
you know better.
Then when you know better,
do better.

-Maya Angelou



Literature

Ihde S, Sipic O. Esthetic indication for dental implant treatment and immediate loading (3). Case report and considerations regarding the aspect of the patient's right to self-determination in medical decision-making. *Ann Maxillofac Surg* 2020;10:213-6.

Ihde S, Sipic O. Dental implant treatment and immediate functional loading (1). Case report and considerations: Extended treatment options using the Strategic Implant® and indications and objectives for comprehensive dental implant treatment. *Ann Maxillofac Surg* 2019;9:465-9.

Ihde S, Palka L. Anchorage possibilities in case of a unilateral maxillary defect using the concept of Strategic Implant®. *Natl J Maxillofac Surg* 2018;9:235-9.

Gaur V, Doshi AG, Gandhi S. Immediate prosthetic rehabilitation of marginal mandibulectomy post radiation case by single-piece implant - A case report. *Ann Maxillofac Surg* 2020;10:501-6.

Gaur V, et al., Mandibular reconstruction using single piece zygomatic implant in conjunction with a reinforcing Fibular Graft Union: A case report, *Int J Surg Case Rep* (2020)

Ahmad A.G. , M. Osman, F. Awadalkreem, Full-mouth rehabilitation of a patient with cleidocranial dysplasia using immediately loaded basal implant-supported fixed prostheses: a case report, *Int. J. Surg. Case Rep.* 65 (2019) 344–348

Singh M., R. Batra, D. Das, S. Verma, A novel approach for restoration of hemisected mandibular first molar with immediately loaded single piece BCS implant: a case report, *J. Oral Biol. Craniofac. Res.* 7 (2017) 141–146

Awadalkreem F, Khalifa N., Ahmad A.G., Suliman A.M., Osman M. Prosthetic rehabilitation of maxillary and mandibular gunshot defects with fixed basal implant-supported prostheses: A 5-year follow-up case report *International Journal of Surgery Case Reports* 68 (2020) 27–31

Konstantinovic V.S., Laazic V.M., Ihde S. Nasal Epithesis Retained by Basal (Disk) Implants *J Craniofac Surg* 2010;21: 33-36

Awadalkreem F, Ahmad AG, Ihde S, Osman M. Effects of corticobasal implant protrusion inside the nasal and maxillary sinus. *Ann Maxillofac Surg* 2020;10:114-21

Lazarov A. A prospective cohort study of maxillary sinus complications in relation to treatments with Strategic Implant® penetrating into the sinus. *Ann Maxillofac Surg* 2020 Jul-Dec;10(2):365-369.

Lazarov A. A prospective cohort study of maxillary sinus complications in relation to treatments with Strategic Implant® penetrating into the sinus. *Ann Maxillofac Surg* 2019 Jan-Jun;9(1):78-88

Pałka ŁR, Lazarov A. Immediately loaded bicortical implants inserted in fresh extraction and healed sites in patients with and without a history of periodontal disease. *Ann Maxillofac Surg* 2019;9:371-8.

Dobrinin O., Lazarov A, Konstantinovic V.K., et al. Immediate-functional loading concept with one-piece implants (BECES/BECES N /KOS/ BOI) in the mandible and maxilla- a multi-center retrospective clinical study. *J. Evolution Med. Dent. Sci.* 2019;8(05):306-315, DOI: 10.14260/jemds/2019/67

Gosai H., Anchilla Sonal, Kiran Patel, Utsav Bhatt, Phillip Chaudhari, Nisha Grag. Versatility of Basal Cortical Screw Implants with Immediate Functional Loading *J. Maxillofac. Oral. Surg.* 2021, <https://doi.org/10.1007/s12663-021-01638-6>

Lazarov AB. The impact of diabetes, smoking, and periodontitis on patients' oral health related quality of life after treatment with corticobasal implants - An evaluative study. *Ann Maxillofac Surg* 2021;11:253-60.

Awadalkreem F, Khalifa N, Satti A, Suleiman AM. The influence of immediately loaded basal implant treatment on patient satisfaction. *Int J Dent* 2020;2020:6590202.

Sipic O., Ihde S. Dental implants in extraction sockets and periodontally involved bone areas: The Technology of the Strategic Implant® radically changes treatment possibilities *CMF Impl Dir* 2021; 15: 190 - 201